

# Chronic and severe prosthetic joint infection complicated by amyloid A amyloidosis with renal and bladder impairment

Nicolas Benech,<sup>1</sup> Sebastien Lustig,<sup>1,2,3,4</sup> Christian Chidiac,<sup>1,2,4,5</sup> Tristan Ferry,<sup>1,2,4,5</sup> on behalf of Lyon BJI Study group

<sup>1</sup>Service de Maladies Infectieuses et Tropicales, Hôpital de la Croix-Rousse, Hospices Civils de Lyon, Lyon, France

<sup>2</sup>Université Claude Bernard Lyon 1, Lyon, France

<sup>3</sup>Service de Chirurgie Orthopédique, Centre Albert Trillat, Hôpital de la Croix-Rousse, Hospices Civils de Lyon, Lyon, France

<sup>4</sup>Centre Interrégional de Référence des Infections Ostéo-articulaires complexes (CRIOAC Lyon), Hospices Civils de Lyon, Lyon, France

<sup>5</sup>Centre International de Recherche en Infectiologie, CIRI, Inserm U1111, CNRS UMR5308, ENS de Lyon, UCBL1, Lyon, France

## Correspondence to

Dr Tristan Ferry,  
tristan.ferry@univ-lyon1.fr

Accepted 22 January 2018

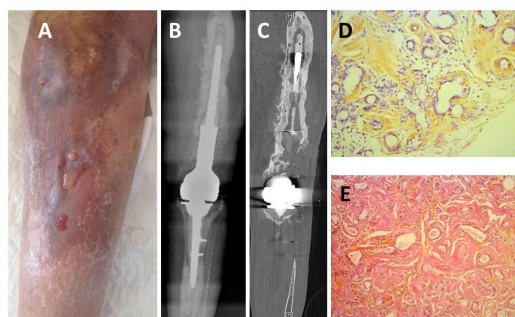
## DESCRIPTION

A 66-year-old woman presented with renal failure and purulent discharge associated with a chronic prosthetic joint infection (PJI) of the left knee. Her medical history consisted of an untreated chronic hepatitis B and recurrent giant-cell tumour of bone revealed by spontaneous fractures 20 years previously. Multiple tumour resections led to knee prosthesis implantation in 1992 with no tumour relapse thereafter. The patient experienced a methicillin-susceptible *Staphylococcus aureus* chronic PJI in the following months that required two-stage prosthesis replacement and a prolonged antibiotherapy. A clinical suspicion of superinfection was confirmed in 2002 by a puncture of the synovial fluid that found a methicillin-resistant *Staphylococcus epidermidis*. The patient declined both surgical and medical treatment and was lost to follow-up.

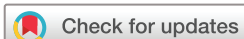She subsequently presented in 2015 with partial impotence, no flexion of the left knee and multiple fistulae with purulent discharge (figure 1A) that had evolved for years and that had been treated with a self-made bandage. X-ray (figure 1B) and CT scan (figure 1C) found extensive periosteal reaction of the femur, bone destruction and prosthesis loosening. Lab results found inflammatory syndrome (C reactive protein: 69.5 mg/L), normocytic anaemia (77 g/L haemoglobin) and a stage 4 chronic kidney disease (glomerular filtration rate: 26.3 mL/min

vs 110 mL/min in 2011; Chronic Kidney Disease Epidemiology Collaboration equation); proteinuria (1.58 g/24 hours) was associated. She also reported transient recurring macroscopic haematuria. Renal echography found kidneys of normal size with no cysts or sign of obstruction. Biopsy of the minor salivary glands found AA amyloid deposits and serum amyloid A protein positive staining (figure 1D,E). Screening for autoantibody and cryoglobulinaemia was negative. Serum protein electrophoresis found polyclonal gammopathy. Bladder biopsies under cystoscopy were also positive for AA amyloid deposits. After evaluation of the risk-benefit ratio, the nephrologist considered that a kidney biopsy was not required to confirm the diagnosis, as two histological samples shown AA amyloid deposits, and other diagnosis were unlikely. A transfemoral amputation of the left leg was performed, followed by an empirical antibiotherapy with daptomycin 350 mg/day and clindamycin 1800 mg/day. Medical treatment was discontinued after 10 days because of an allergic reaction with cutaneous rash and acute renal failure that resolved after cessation of treatment. Culture of the resected bone did not identify any causal organism for the infection: 1/5 samples was positive for *Propionibacterium acnes* considered as a contaminant. The patient presented no relapse of infection but required chronic dialysis and a cystectomy for recurring haematuria with severe haemorrhaging 3 months later.

AA amyloidosis is a rare complication of chronic inflammatory disorders such as chronic bacterial infections. AA amyloid fibrils are derived from serum amyloid A protein and accumulate in tissue leading to organ dysfunction.<sup>1</sup> In the largest published cohort of 374 patients with AA



**Figure 1** Chronic prosthetic joint infection of the left leg causes AA amyloidosis. Clinical aspect of the left leg after 13 years of chronic infection: cutaneous fistula with purulent flow and inflammation of the dermis (A). X-ray (B) and CT scan (C) findings showing extensive periosteal reaction and bone destruction of the left femur with prosthesis loosening. Histological findings of the minor salivary glands: haematoxylin phloxine saffron stain with amyloid fibrils (D) that are red Congo positive (E).



**To cite:** Benech N, Lustig S, Chidiac C, et al. *BMJ Case Rep* Published Online First: [please include Day Month Year]. doi:10.1136/bcr-2017-223491

## Learning points

- ▶ Amyloid A (AA) amyloidosis is a possible complication of untreated chronic osteomyelitis or prosthetic joint infection.
- ▶ Unexplained chronic kidney disease with proteinuria in a context of chronic bone and joint infection should lead to search for AA amyloidosis through minor salivary glands biopsy.
- ▶ Even after infection resolution, renal prognosis remains poor for AA amyloidosis with kidney disease.

amyloidosis, osteomyelitis was the underlying disease for 1.3% of patients (5/374).<sup>1</sup> Renal dysfunction is reported to be the predominant disease manifestation with a poor functional prognosis particularly when renal dysfunction was severe at diagnosis.<sup>2</sup> This rare but mainly irreversible complication should be discussed with patients with extended infection of large tumour prosthetic joints and who decline therapeutic strategies.

**Acknowledgements** We would like to thank the Lyon Bone and Joint Infection Study Group. We acknowledge Dr Diane Collet-Benzaquen, who performed the pathology and sent us the microscopic pictures.

**Collaborators** Lyon Bone and Joint Infection Study Group include: Coordinator: Tristan Ferry; Infectious Diseases Specialists: Tristan Ferry, Florent Valour, Thomas Perpoint, André Boibieux, François Biron, Patrick Mialhes, Florence Ader, Agathe Becker, Sandrine Roux, Claire Triffault-Fillit, Anne Conrad, Alexie Bosch, Fatiha Daoud, Johanna Lippman, Evelyne Braun, Christian Chidiac; Surgeons: Sébastien Lustig, Elvire Servien, Romain Gaillard, Antoine Schneider, Stanislas Gunst, Cécile Batailler, Michel-Henry Fessy, Yannick Herry, Anthony Viste, Philippe Chaudier, Romain Desmarchelier, Cyril Courtin, Lucie Louboutin, Sébastien Martres, Franck Trouillet, Cédric Barrey, Francesco Signorelli, Emmanuel Jouanneau, Timothée Jacquesson, Ali Mojallal, Fabien Boucher, Hristo Shipkov, Joseph Chateau, Jean-Thomas Bachelet; Anesthesiologists: Frédéric Aubrun, Mikhail Dziadzko, Caroline Macabéo; Microbiologists: Frederic Laurent, François Vandenesch, Jean-Philippe

Rasigade, Céline Dupieux; Imaging: Fabien Craighero, Loic Bousset, Jean-Baptiste Pialat; Nuclear Medicine – Isabelle Morelec, Marc Janier, Francesco Giammarile; PK/PD specialists: Michel Tod, Marie-Claude Gagnieu, Sylvain Goutelle; Prevention of infection: Solweig Gerbier-Colomban; Clinical Research Assistant: Eugénie Mabrut.

**Contributors** TF, SL and CC participated to the patient care. NB wrote the draft of the manuscript. All authors significantly improved the manuscript and approved its final version.

**Funding** This research received no specific grant from any funding agency in the public, commercial or not-for-profit sectors.

**Competing interests** None declared.

**Patient consent** Obtained.

**Provenance and peer review** Not commissioned; externally peer reviewed.

© BMJ Publishing Group Ltd (unless otherwise stated in the text of the article) 2018. All rights reserved. No commercial use is permitted unless otherwise expressly granted.

## REFERENCES

- 1 Lachmann HJ, Goodman HJ, Gilbertson JA, *et al*. Natural history and outcome in systemic AA amyloidosis. *N Engl J Med* 2007;356:2361–71.
- 2 Scarpioni R, Ricardi M, Albertazzi V. Secondary amyloidosis in autoinflammatory diseases and the role of inflammation in renal damage. *World J Nephrol* 2016;5:66–75.

Copyright 2018 BMJ Publishing Group. All rights reserved. For permission to reuse any of this content visit <http://group.bmj.com/group/rights-licensing/permissions>.  
BMJ Case Report Fellows may re-use this article for personal use and teaching without any further permission.

Become a Fellow of BMJ Case Reports today and you can:

- ▶ Submit as many cases as you like
- ▶ Enjoy fast sympathetic peer review and rapid publication of accepted articles
- ▶ Access all the published articles
- ▶ Re-use any of the published material for personal use and teaching without further permission

For information on Institutional Fellowships contact [consortiasales@bmjgroup.com](mailto:consortiasales@bmjgroup.com)

Visit [casereports.bmj.com](http://casereports.bmj.com) for more articles like this and to become a Fellow